


# L'EXPANDER

The plastic surgery newsletter from Laboratoires SEBBIN



## EDITORIAL by Olivier Pérusseau



You may know that since Laboratoires Sebbin was taken over by PVP-SAS a little over a year ago, it has taken on new momentum. Since working ethically is such a priority to us, we have entered our company into close partnership with plastic and reconstructive surgery professionals. It is in this context that you will regularly receive our plastic surgery newsletter. Here, therefore, is the first issue of L'Expander. We hope that it will be of

use to you in adding to your knowledge, not only in terms of implant surgery but also in the most up-to-date medical and surgical techniques. You will also come across articles that over time will tell the story of your profession.

We made Doctor Julien Glicenstein the editor-in-chief of L'Expander so that you would have at your disposal the skill and experience of a talented and passionate professional.

Do not hesitate to send us your comments and suggestions, which we would welcome with great interest.

Happy reading.

# A FEW WORDS from Doctor Julien Glicenstein

Laboratoires Sebbin wanted to help plastic surgeons by bringing out this newsletter. L'Expander will take a broad look at interesting topical subjects in our field. It will feature article reviews, clarifications, conference reports and historical articles. All your suggestions will of course be welcome.



## CONTENTS of ISSUE 1:

- Facial transplantation by Prof. Méningaud ..... p2
- Breast augmentation, antibiotics and infection..... p7
- Method for preparing fat transplantation..... p8
- Treatment of hemangiomas by beta blockers ..... p9
- Complications of surgery following weight loss..... p9
- Fat transplantation in reconstructive surgery of the breast following cancer..... p10
- Yesterday/today:  
Breast augmentation by injection ..... p11
- A look back at the history of transplants:  
Garegeot's nose..... p12

## L'EXPANDER'S guest contributor

At the launch of L'Expander, Professor Jean-Paul Méningaud, university professor/hospital doctor of the Créteil Henri Mondor Hospital, maxillofacial surgery and facial plastic surgery specialist, has done us the honour of starting us off with an article on this delicate procedure and the conditions required to ensure its success.



# FACIAL TRANSPLANTATION.

The term "face transplant" is a handy phrase but does not reflect the reality of what is actually transplanted. Indeed, the face reflects the personality of its owner, particularly through expressions that are unique to each individual. The face is an anatomical entity with all the physical structures that this includes. The type of transplantation involved here is that of the face. The recipient imprints his/her emotions onto it. The face of the donor becomes that of the recipient.

### INDICATIONS

Conventional techniques allow the vast majority of facial disfigurements to be treated. Beyond a certain level of severity, some types of substance loss - traumatic or acquired (tumour) - cannot be repaired functionally or aesthetically. The current state of our knowledge means that we do not know how to repair the orbicularis muscle (lips, eyelids) if it has been totally destroyed.

In order to repair damaged structures, sufficient residual tissue has to be available. These patients are not neglected; on the contrary, they often undergo surgery between 20 and 50 times, but the final result is always disappointing, both functionally and aesthetically.

A very common mistake is to think that the face is just a superficial plastic entity that allows us to recognise each other. This aspect should not be forgotten, however, because a minimal level of appearance is necessary in order to be able to carry out most social functions. Once someone's face is disfigured beyond a certain level, their social life diminishes. However, the face is a lot more than a social interface; it is also an organ.

The face allows or facilitates functions as basic as eating, salivating, chewing, swallowing, prevention of burning, prevention of dribbling, kissing, protecting the eyes, breathing, warming inhaled air and speaking. In this respect, patients requiring a face transplant are making a functional request. Some of our patients were unable to carry out any of the above functions and were condemned to tracheotomy and gastrostomy. In practice, most patients who are candidates for a face transplant have ballistic trauma or burns. Another category is patients with a specific form of neurofibromatosis that severely affects the face.

## MEDICAL/LEGAL FRAMEWORK

In France, the approvals that have been requested have involved the National ethics committee, whose mission is to give opinions on ethical problems raised by the progress of knowledge, the Biomedicine agency, which substitutes for the French transplantation associations, the French agency for the safety of health products, which guarantees quality and proper use of all products used in humans, particularly tissue of human origin, and committees for the protection of persons, which together give approval for biomedical research. Indeed, the hospital clinical research programme allows costly research to be funded, provided that ethical recommendations

are respected, contributing indirectly to the control of these interventions which, today, remains within the context of biomedical research. Specific consent and insurance are given.

## PREPARING PATIENTS

The criteria defined above are necessary but are not sufficient. There are also fundamental psychological criteria. It is essential that the patient is mentally balanced. Most often, disfigurement requires psychotropic treatment because of its cause or repercussions. This type of recovery can take several months or years. Repeated interviews with a psychiatrist and psychologist are necessary so that everything can be verbalised. A clinical and paraclinical checkup is carried out. In particular, this includes HLA typing, antibody screening and human immunodeficiency virus, hepatitis, cytomegalovirus and herpes serologies. An angiography scan of the supraortic branches allows the recipient vascular branches to be repaired. An electromyogram pinpoints residual facial and trigeminal activities. Screening for infectious foci is carried out with microbiology samples, and dental, otorhinolaryngeal and pulmonary checkups.

## ON THE ALERT

If a potential deceased donor is identified, the information compulsorily passes to the Biomedicine agency, which relays the information according to the patients on the waiting list. A selection is made according to criteria based on ABO group, sex, phototype, geographical proximity and other immunological criteria. Most commonly, the recipient's department is alerted before the family gives final approval, so false alarms are common. This situation is paradoxical because in France consent is presumed. There is an organisation and a *modus vivendi* that mean that eventually the waiting time is longer than that in Spain. A considerable amount of energy is wasted at least 4 times out of 5.

## HOSPITAL COORDINATION OF THE TISSUE

The complexity of transplantation activities, which combine ethical and psychological dimensions with the technical dimension in a naturally urgent context, has led to the introduction of hospital structures for coordinating samples and transplants.

Their principal aims are:

- . To ensure that families of potential deceased donors are received under the best possible material and psychological conditions. (Prior examination of the national register of refusals is also within their remit);
- . To facilitate the working of teams whose job it is to take the samples; their support is important also from a psychological point of view, many doctors are not used to allotransplantation work;
- . To actively participate in the local and regional organisation of transplantation activities;
  - To improve the general quality of samples;
  - To oversee health safety;
  - To increase the number of available transplants by way of information campaigns;
  - To relay the available information to various parties involved.

## SURGERY ON THE DONOR

The maxillofacial surgeon is the first to be involved, before the other surgical disciplines (urology, liver surgery, cardiac surgery). The first stage consists of freeing the face (of catheter, tubes) and carrying out a tracheotomy. Then a mould of the face is made so that a resin mask can be constructed that allows the cadaver to be returned to the family in a dignified way after the sample has been taken. The number of anatomical structures the surgeon takes depends on the type of trauma of the recipient. For example, for the lower face, the surgeon may take at the same time two facial nerves, the orbicularis oris, the second and third branches of the trigeminal nerve, the toothed part of the mandible, the largest part of the maxilla, the parotids with the parotid ducts, the whole of the nasal

pyramid and, of course, all of the skin and mucous membrane structures.

Once the tissue is taken, it must all be attached to the two arterial and venous branches. As a general rule, these are the external carotids and thyrolinguofacial trunks.

Tissue for an upper face transplant includes in addition the eyelid structures, i.e. the orbicularis, the levator muscle, the lacrymal ducts, the conjunctivae and possibly the lacrymal gland. The temporal pedicle has to be taken. For an upper face transplant the whole face has to be taken and then the parts not used are removed. Anatomically, the scalp and the external ear are not part of the face, but may be removed with it.

## SURGERY ON THE RECIPIENT

Surgery on the recipient begins at the same time. Firstly, the scar tissue is ablated.

In the case of neurofibromatosis, this stage may be particularly difficult because of bleeding. The blood vessels (external carotids, thyrolinguofacial branches) and receiving nerves (branches of the facial nerves, branches of the trigeminal nerves) are then located. This stage is difficult if the patient has had multiple operations or is a burns patient.

The transplant tissue is brought in, bathed in a transport solution in a refrigerated box. It is rinsed, then arterial anastomosis is carried out. Venous anastomosis is then carried out and then contralateral anastomoses, osteosynthesis and nervous anastomosis.

### THE SEBBIN WEBSITE HAS A NEW LOOK AT SEBBIN.COM!



Finally, the mucous membrane and skin are sutured.

### ANTI-REJECTION THERAPY

For our team, the introductory immunosuppressant treatment consists of thymoglobulin (human antithymocyte immunoglobulin) at a dose of 1 mg/kg/day for 10 days in total, oral tacrolimus (Prograf) at a dose to maintain plasma levels at 10-13 ng/ml, mycophenolate mofetil (Cellcept) at a dose of 2 g/day (dose necessary to maintain an AUC of 40-60 ng/ml) and prednisone (500 mg on day 1, 250 mg on day 2, 120 mg on day 3 and then 60 mg/day for 7 days and then a gradual reduction to 10 mg/day). Photopheresis (extracorporeal photochemotherapy) is used as an adjuvant immunomodulator treatment.

### THE IMPORTANCE OF REHABILITATION

From the day after the surgery the long process of readjustment of the transplant recipient begins, with its moments of high emotion, checking in the mirror, the first request for local anaesthetic during a biopsy (recovery of sensitivity), the first smile, the first walkabout where the patient passes unnoticed, going back to work, etc. Rehabilitating transplant patients is essential. This involves physiotherapists and speech and language specialists. The main aim is talking again. Many of these patients have had a tracheotomy for several years prior to the transplant, have ankyloglossia and cannot close their lips, or in the opposite case cannot open their mouth wide. The transplant indeed allows suitable rehabilitation to be effective and to remove these patients from their world of silence.

### TIME TO FUNCTIONAL RECOVERY

If the sensory nerves are connected, recovery of sensitivity is quite rapid. From the fourth month, the patient requests local anaesthetic during checkup biopsies of the skin or mucous membranes. This takes a short time and

is therefore quite surprising. Antirejection therapy is at the heart of this fortunate side effect. If these nerves are not connected, recovery of sensitivity is of less good quality allowing some level of proprioception. Recovery of motor function is fundamental. It would be inconceivable to carry out a face transplant without connecting the facial nerves. The start of recovery begins at about 6 months. Gradually, the patient imparts his/her own expressions onto the transplanted tissue. Wrinkles such as the nasomental line form more or less intensely.



### MEET UP WITH LABORATOIRES SEBBIN:

Euro-Pharmat workshops from 11 to 13 October 2011 in Lyon

56th National Conference of the SOF.CPRE from 21 to 23 November 2011 at CNIT PARIS la Défense

### NEUROLOGICAL EVIDENCE OF RECOVERY

Neurological evidence of recovery is seen simply in clinical observation. If a patient smiles broadly, there is no longer any doubt. However, recovery is monitored by electromyography. This examination allows deficient recovery to be detected and may also indicate that surgery on a nervous anastomosis is also necessary (we have already had one case of this nature).

## THE IMPORTANCE OF PSYCHOLOGICAL AND PSYCHIATRIC MONITORING

Psychological and psychiatric monitoring is fundamental. It helps the patient adjust to their new life, their new face and to start afresh. Repeated interviews are necessary. An analysis of family functioning is an important piece of information. Psychotropic drugs may be used. Their dose needs to be reassessed regularly. The patient's mental state needs to be managed before the transplantation, and this will continue after the surgery, due to anxiety generated by the intensive surgery, the transplant, possible media involvement, etc. and interactions with antirejection therapy (e.g. high dose corticoids may cause mental decompensation).

## PATIENT SATISFACTION

One cannot rely on the patient's enthusiasm alone to know that he/she is satisfied. Their satisfaction should be analysed objectively using quality of life evaluation scales. These scales allow different aspects of what could be called a full life to be classified. An overall score makes comparisons with respect to standard populations and the patient him/herself over time. In this respect, the return to work is a very important indicator (3 of our patients returned to work).

## Did you know?

- All Laboratoires Sebbin implants are checked individually by hand at all stages of manufacture
- Parameters relating to the gel and envelope are checked before and after heating
- All products have CE certification
- The harmlessness of the raw materials has been recognised by the FDA (Food and Drug Administration)
- Cohesiveness is checked every day.

## ARTICLE REVIEWS

# BREAST AUGMENTATION, ANTIBIOTICS AND INFECTION...

*Breast implant from Laboratoires Sebbin*

*Breast augmentation. Antibiotic prophylaxis and Infection. Comparative analysis of 1628 primary augmentations assessing the role and efficacy of antibiotic prophylaxis duration*

*Khan UD*

*Aesth. Plast Surg 2010, 34:42-7*

Should antibiotics be prescribed for prophylactic purposes during breast implantation? This question has been asked from the time of the first breast augmentation operations. Septic complications of the surgery seemed rare, exceptional even, when implants were introduced for aesthetic reasons. Since then, various authors have reported minimal infections (Mondor disease, leaking, local discharge), which poses a new question: can implants be preserved using a local or general treatment? The author puts forward

a retrospective study of 1628 prosthetic breast augmentations (3256 breasts) over a 10-year period. Nearly half were subglandular prostheses, 46% by the dual plane technique (superior submuscular part), and the rest were submuscular. Most patients received a perioperative injection of cephalosporin followed by 5 days of oral treatment (75%). For others, the perioperative injection was not followed by any postoperative treatment, or a single day of oral antibiotics. The authors distinguish superficial infections (local detachment, infection on a thread) and deep infection with local signs (oedema, redness of breast).

The results of preventative treatment seem to have an advantage over a single injection of perioperative antibiotics.

# PREPARATION OF FAT TRANSPLANTS: WHAT TECHNIQUES SHOULD BE USED?

*Effects of fat preparation methods on the viability of autologous fat grafts*

*Minn Kw, Min KH, Chang H, Kin S, Heo EJ. Aesth Plast Surg 2010, 34:626-31.*

Autologous fat transplants are gaining more interest and have an increasing number of applications. Unfortunately, this is a technique with unpredictable results because of partial reabsorption of the fat. Many factors come into play: the method and site from where the tissue is taken, the age of the patient, the area where the fat is reinjected. Many recently published articles show that the choice of method of removing the tissue is based much more on empirical evidence than on scientific conclusions. The authors took fat using a syringe from unused parts of the TRAM flaps and purified it in three ways: centrifugation, filtering through a metal "sieve", and decantation on a compress. The fat purified in these three ways was then injected into mice, sacrificed at 12 weeks old. The injected fat was then removed and weighed. No difference was observed between the survival rates of adipose cells. Only fat filtered through a sieve displayed any notable inflammatory phenomena.

The authors thought that centrifugation (that was performed for three minutes) had few advantages over simple decantation over a compress. Other articles have shown the complexity of the problem and the number of factors to be analysed (fat removal technique with or without infiltration, duration of centrifugation, amount reinjected, etc.) For the moment, personal experience prevails over experimentation...





## TREATMENT OF HEMANGIOMAS BY BETA BLOCKERS.

*Propranolol as first line treatment of proliferating infantile hemangiomas*  
*Holmes and al. J Plast Reconstr Aesth Sup. 2011;44, 445-51*

Ten per cent of hemangiomas in babies require treatment due to obstruction of an essential organ (eye, respiratory tracts) or ulceration. From the 1970s to the start of the 21st century, corticoid treatment came to the fore. Since then, the use of propranolol, a beta blocker, has been shown to be effective in stopping progression, causing regression of progressive or dangerous hemangiomas.

The authors carried out a prospective study in 31 children with this type of lesion who underwent cardiovascular monitoring. The treatment was started at an oral dose of 0.5 mg/kg, and pulse, blood pressure and possibly blood glucose were checked every 15 minutes in the 2 hours following absorption of the medicine. The children then received 2 other doses and some were treated in the outpatient department at a dose of 3 mg/kg/day 3 times. They were closely monitored (blood pressure, pulse, blood glucose).

The patients were seen again after one week and then two weeks and every week for the duration of the treatment. Photographs were used to check progress. Treatment was stopped when the progression stabilised. If the disorder again became progressive, the treatment was restarted at the same dose.

Progressive growth of the hemangioma was stopped in 100% of patients and in 87% regression was significant. The treatment was well tolerated, with few side effects (transient hypotension in one patient, rebound in another). According to the authors, propranolol treatment should be used in the first place in progressive hemangiomas and in those whose location may have serious consequences.

## COMPLICATIONS OF SURGERY FOLLOWING WEIGHT LOSS

*Complications in Postbariatric Body Contouring Post operative management and treatment*  
*Michaels J and Al. Plast Reconstr Surg 2011, 127 : 1693-1700*

Post-weight loss reparative surgery is a branch of plastic surgery experiencing full development, but the number of complications is still much higher than following traditional cosmetic surgery procedures. The authors analysed these complications and the methods used to prevent them. They recommend drainage for 10-14 days, compressive garments for 3 weeks, a diet that includes a minimum of 70 g protein a day and early mobilisation. In 700 patients who underwent surgery, the authors found that 42% developed complications. Haematoma occurred in 1-5% of patients, seroma in 15% and to prevent these the authors recommend leaving in aspirative drainage if giving more than 30 ml/day. They warn against a too deep dissection of the skin at some sites (internal side of the knee, for example), promoting opening of the lymphatics. Scar dehiscence was common, reaching 22% according to the authors' statistics. Excessive resection of the skin may be the cause of excessive tension and skin necrosis (6-10%).

A careful study of the size of resections should prevent the recurrence of scarring, common for "ears" and residual lymphoedema.

The greatest risk is of course thromboembolic disease. The authors did not report their statistics or the existence of postoperative death.

And as the authors conclude, we should try to prevent these complications and protect future patients who undergo surgery from this risk.

# RECONSTRUCTIVE SURGERY OF THE BREAST FOLLOWING CANCER: WHAT ABOUT FAT TRANSPLANTS

*Safety of fat grafting in secondary breast reconstruction after cancer.*  
 Rietgens M, and al. *J Plast Reconst Aesth Surg* 2011, 64, 477-84

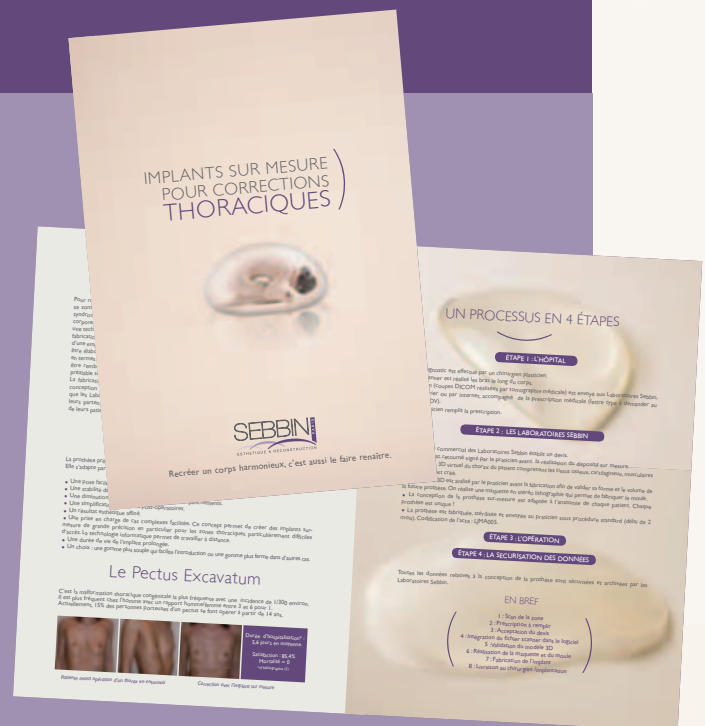There are many articles about fat injections into the breasts for the purposes of augmentation or for correction following cancer surgery. It was in this latter indication that a team from the European Oncology Institute of Milan treated 158 patients (195 breasts) prospectively: 78 following quadrantectomy, 114 following mastectomy and 3 for benign conditions. Sixty-eight of the 195 breasts treated for cancer underwent radiotherapy.

The authors removed the fat following extensive infiltration using Coleman's technique (10 ml then 1 ml syringes, centrifugation for 3 min at 3000 r/min). They were sad to report 7 complications (liponecrosis and infection), which required dressings and antibiotics. Pre- and postoperative mammographies were systematically compared and in 4 postoperative mammographies completely benign and minor abnormalities were found. One patient had a relapse of her cancer during the six-month follow-up period.

The authors considered the results to be very satisfactory. Most of the patients received a single injection (16% received several). The mean amount injected was 48 ml. It was judged, however, that the extent of reabsorption, which varied, was underestimated. Radiotherapy seemed to be the main factor in complications.

To respond more specifically to the requirements of reconstructive surgery, Laboratoires Sebbin has become involved in corrective surgery of the chest: pectus excavatum ("funnel chest"), Poland syndrome and all other body deformities. With the help of specialist partners they have designed computer-assisted 3D technology that allows custom-made implants to be made.

Do not hesitate to contact us to find out more.



New Sebbin brochure on chest implants

YESTERDAY TODAY

AUGMENTATION BY INJECTION:  
A LONG HISTORY.

Breast augmentation by fat injection or hyaluronic acid is in fashion at the moment. Since people began to want larger breasts, i.e. from the beginning of the 20th century, the first idea was to inject a stable, harmless product. The first person to do this, the Austrian Gersuny, perfected paraffin injections, which were later replaced by one of its derivatives, vaseline, the properties of which seemed to be ideal for stable, durable retention in the human body: injection in liquid form, solidification and the need to be liquefied again at a very high temperature is incompatible with life. It was generally received enthusiastically and more than 100 articles were published between 1900 and 1903. Unfortunately, after a few years of use, particularly in the face ("saddleback nose"), complications started to appear.

Hyppolite Morestin (1869-1919), the "father" of French plastic surgery, in a letter to the Surgery Society of Paris, denounced the "drawbacks and abuses of paraffin injections " from 1908 [1]. Morestin did not reject the principle of the technique, but criticised "dangerous applications" and "regrettable abuses".

The observation he made was regarding a young woman with a strange breast tumour who confessed to having undergone four injections of 5 cm<sup>3</sup> paraffin in each breast three years ago. Just one of her breasts had a more or less inflammatory mass, which relapsed despite surgical curettage. Morestin did not condemn paraffin injections (the practice of which continued for about fifty years with catastrophic consequences) but advised against their use for breast augmentation.

He finished his letter by citing another observation of a young man who had undergone paraffin injections into his penis in order to enlarge its volume three years ago. Morestin could only remove the paraffin by a difficult operation with complicated sequelae. Paraffin injections into the breasts or penis were not the only sites to result in complications. In the 1960s, liquid silicone injections were very successful, particularly in Asia, with the same catastrophic consequences.

To be continued...

[1] Morestin H. *Inconvénients et abus des injections de paraffine. Bull Soc Chir Paris (1908 34 : 1 24-8.)*

Saturday 9 July 2011

SEBBIN WORKSHOP

Gluteal implantation by Dr Philippe Levan.  
This surgery workshop has taken place at  
Clinique Elysée Montaigne, Paris 8th district.

Coming soon on [www.sebbin.com](http://www.sebbin.com)!  
The Sebbin workshop on line! Check our website!

# A LOOK BACK AT THE HISTORY OF TRANSPLANTS

## CHAPTER I: GARENGEOT'S NOSE

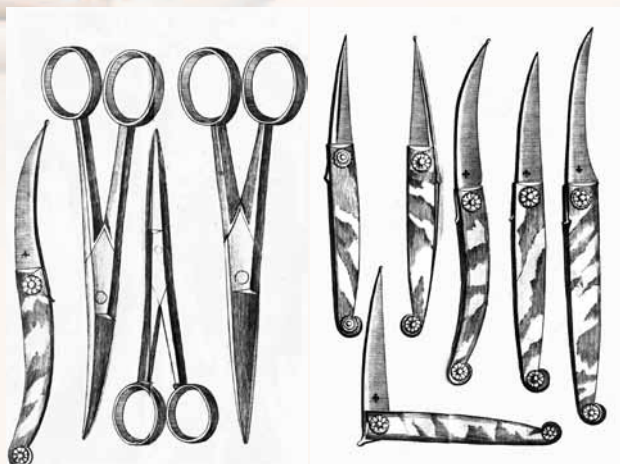Doctors have always thought that it was possible to reattach a fragment of the body that had become unattached such as a nose or ear, but reports were anecdotal and based on witness reports of "so-and-so who knew someone who saw..." The Tagliacozzi technique appraised by Ambroise Paré was discredited, and during the Enlightenment the success of reattachment of a nose removed by a bite or axe was disbelieved. In his work "Rhinoplastie" (1840), Léon Labat reported that on "26 September 1724, two soldiers of the Conti Regiment were drunk at a cabaret and were arguing and fighting in the street; one of them gripped the whole of the cartilaginous part of the nose of his adversary with his teeth, ripping it off and spitting it out in the mud. A neighbourhood surgeon called Galain washed the nose in warm wine and reattached it forthwith, and kept it in place with sticking plaster and a sling bandage. From the next day it started to stick".



René Jacques Croissant de Garengéot (1689-1759), military surgeon and member of the Academy of Surgery, had the opportunity to examine the injured man four days after his accident and reported to academics and later in his work that he noted that the fragment of nose was perfectly living and healed.

Surgeons at the time were at first not surprised. But some years later, a man called Montsaulieu wrote a pamphlet against Garengéot, and triggered a wave of criticism and mockery. The greatest surgeons of the time, from France and from abroad, (Morand Winslow, Petit, Heister) said Garengéot acted in bad faith and they did not believe him. The end of Garengéot's life was saddened by this polemic and his tarnished reputation. However, some surgeons began to research similar reports and in 1863 the Berliner Eduard Zeis (1807-1868) collected more than 280 reports and articles published on the subject between Antiquity and the middle of the 19th century.

From the 1970s to the 20th century, quite a few publications critically examined the reattachment of ears, noses and fingers. These observations are not all credible. Then came microsurgery...



Next issue: *the Baronio sheep* in the second issue of L'Expander...